

ØRE-NÆSE-HALS

■ PATIENTKATEGORIER:

- BEGGE KØN
- ALLE ALDRE: 0-102 ÅR
- BÅDE KIRURGI OG MEDICIN

ØRE-NÆSE-HALS

<u>OMRÅDE</u>	<u>OBJEKTIV UNDERSØGELSE</u>
➤ ØRER	OTO(MIKRO)SKOPI
➤ NÆSE-BIHULER	ANTERIOR RHINOSKOPI
➤ ANSIGT	PALPATION
➤ MUND	INSPEKTION/PALPATION
➤ PHARYNX	POSTERIOR RHINOSKOPI
➤ LARYNX	INDIREKTE LARYNGOSKOPI
➤ TRACHEA-BRONCHIER	ENDOSKOPI
➤ OESOPHAGUS	ENDOSKOPI
➤ HOVED-HALS (+ GL. THYREOIDEA)	PALPATION, UL, FNA

ØRE-NÆSE-HALS

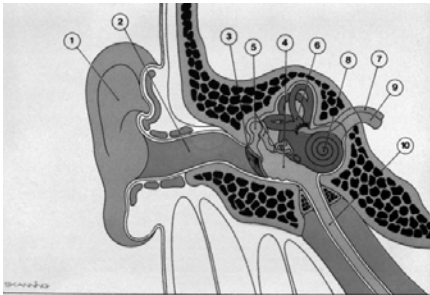
■ ØVRIGE UNDERSØGELSER

- SEROLOGI
- BIOPSI
- RADIOLOGI: RØNGTEN
CT/MR SCANNING
- NUCLEARMEDICIN: SCINTIGRAFI
PET

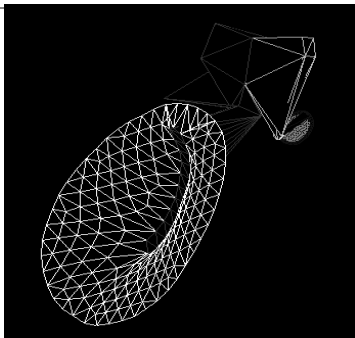
ØRE-NÆSE-HALS

- SYGDOMME:
 - KONGENITTE TILSTANDE
 - TRAUMER
 - FREMMEDLEGEMER
 - INFEKTIONER
 - INFLAMMATIONER
 - TUMORER: BENIGNE
 MALIGN

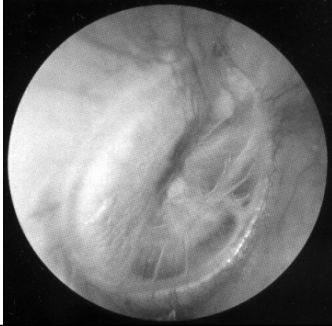
ØRETS ANATOMI



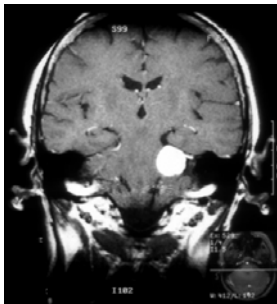
Normal fysiologi



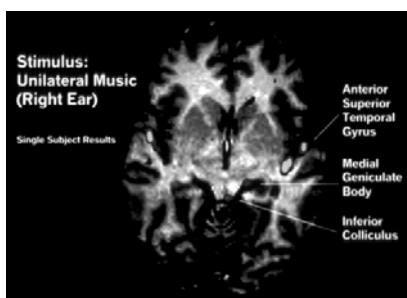
NORMAL TROMMEHINDE



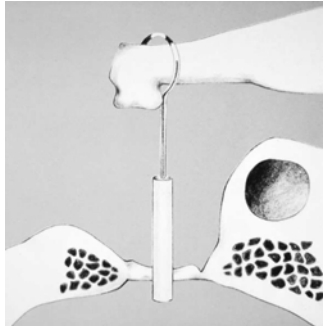
MR-SCANNING AF ACUSTICUS-NEURINOM



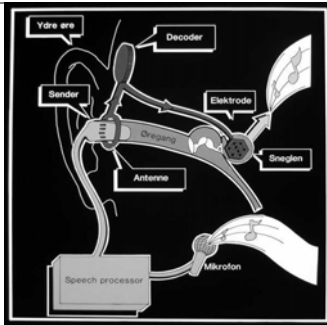
MR+PET SCANNING



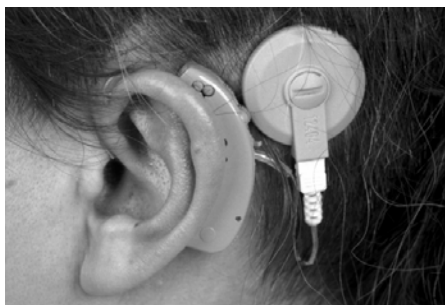HØREFORBEDRENDE OPERATION



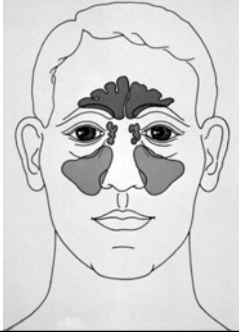
HØREFORBEDRENDE OPERATION



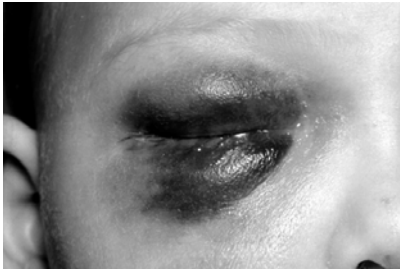COCHLEAR IMPLANT



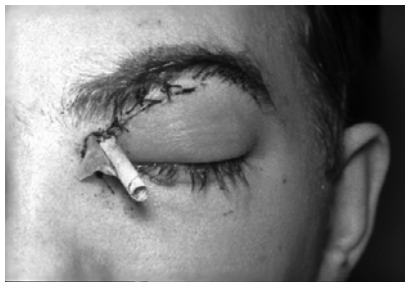NÆSE-BIHULER





AKUT ETHMOIDITIS

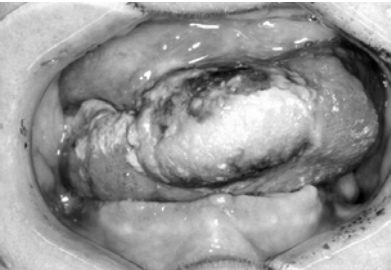


AKUT KIRURGI

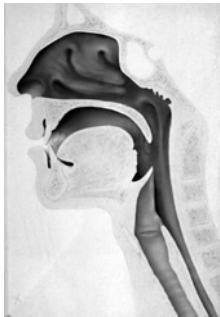

	CAVUM ORIS
TONSILLITIS ACUTA	

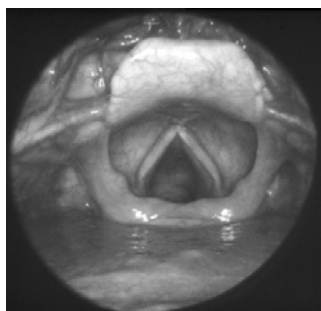
	CAVUM ORIS
CANCER I MUNDBUND	

	CAVUM ORIS
TUNGE CANCER	

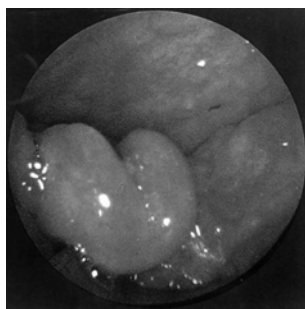
**ØVRE LUFTVEJE OG
OESOPHAGUS**



NORMAL LARYNX

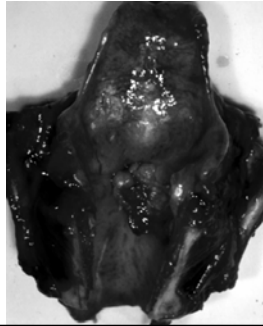


EPIGLOTTITIS ACUTA

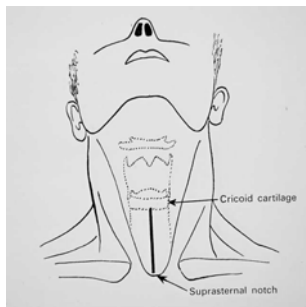


LARYNX CANCER

LARYNGEKTOMI

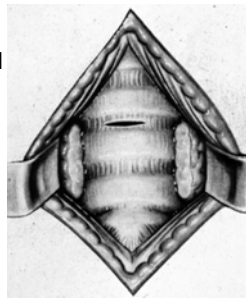


TRACHEOTOMI



TRACHEOTOMI

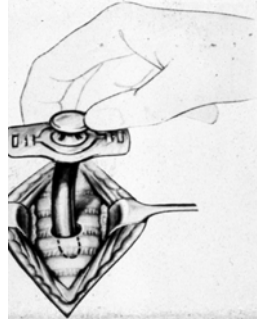
TRACHEA FRILÆGGES
INCISION I FORVÆGGEN



TRACHEOTOMI

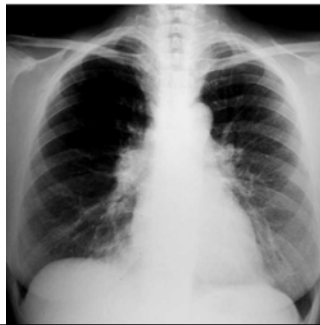FENESTER I TRACHEA
FORVÆG

KANYLE PLACERES



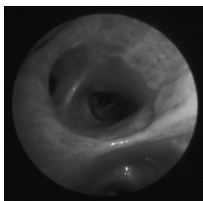
BRONCHIER - LUNGER

LUNGE-CANCER

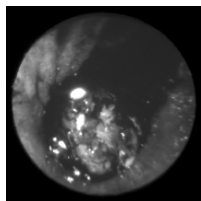


BRONKOSKOPI

NORMAL



CANCER



BRONKOSKOPI

RIGIDT
BRONKOSKOP



EL SLYNGE/KOAGULATOR



OESOPHAGUS

FREMMEDEGEMER:

NÅL

KNAP

KNIV