

## KRONISK OTITIS MEDIA

### DEFINITIONER:

- > *OTITIS MEDIA SUPPURATIVA CHRONICA:*  
PERMANENTE MELLEMLØRE-FORANDRINGER  
MED AKTIVITET
- > *SEQUELAE OTITIDIS:*  
PERMANENTE MELLEMLØRE-FORANDRINGER  
UDEN AKTIVITET

---

---

---

---

---

---

---

---

## KRONISK OTITIS MEDIA

### DEFINITIONER:

- > *Aktivitet: inflammation i mellemøre-mucosa:*

- flåd
- granulationsvæv
- polypper

- > *Kronisk: ???*

---

---

---

---

---

---

---

---

## KRONISK OTITIS MEDIA

### Kronisk:

- Kontinuerligt flåd gennem mere end 3 uger trods relevant behandling
- Recidiverende flåd gennem mere end 8 uger trods relevant behandling

---

---

---

---

---

---

---

---

## KRONISK OTITIS MEDIA

### ● DISPOSITIONER:

SOM VED AKUT OG  
SEKRETORISK OTIT

- INFEKTION
- TUBADYSFUNKTION

---

---

---

---

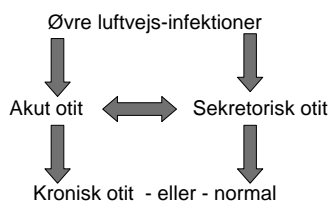
---

---

---

---

## KRONISK OTITIS MEDIA



---

---

---

---

---

---

---

---

## KRONISK OTITIS MEDIA

### ● INDELING:

- *KRONISK SLIMHINDE-OTIT (GRANULERENDE OTIT): "FLYDEØRE"*  
*CENTRAL PERFORATION UDEN CHOLESTEATOM*
- *CHOLESTEATOM: "FLYDEØRE", RAND-STILLET PERFORATION/RETRAKTION, EVT. OSTIT*
- *SPECIFIKKE INFLAMMATORISKE TILSTANDE*

---

---

---

---

---

---

---

---

**KRONISK GRANULERENDE  
OTITIS MEDIA**

● **HYPPIGHED:**

(DK) PRÆVALENS: ~ 1 %  
(GRØNLAND): 10 %  
(U-LAND): 35 %

---

---

---

---

---

---

---

---

**KRONISK GRANULERENDE  
OTITIS MEDIA**

**SYMPTOMER:** INTERMITTERENDE FLÅD  
HØRENEDSÆTTELSE  
SMERTER VED RETENTION

**DIAGNOSTIK:** OTOMIKROSKOPI+AUDIOMETRI  
(OFTEST PARS TENSA-DEFEKT, GRANULERENDE  
SLIMHINDE, SEKRETORISK EPITEL+GLANDLER,  
MUKØST/MUKOPURULENT SEKRET)  
KONDUKTIVT HØRETAB  
SJÆLDENT KOMPLIKATIONER

**BEHANDLING:** TØRLÆGNING + HØREFORBEDRING  
(MYRINGOPLASTIK, EXPLORTIV TYMPANOTOMI,  
EVT. MASTOIDEKTOMI)

---

---

---

---

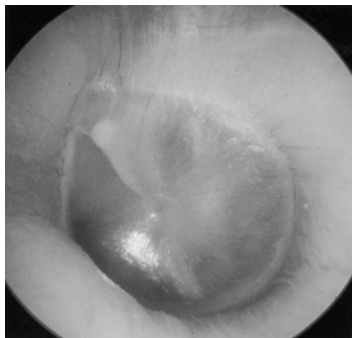
---

---

---

---

**NORMAL TROMMEHINDE**



---

---

---

---

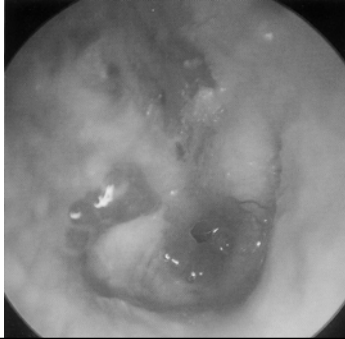---

---

---

---

## KRONISK GRANULERENDE OTIT



---

---

---

---

---

---

---

---

## KRONISK OTITIS MEDIA

### ● CHOLESTEATOM:

"FLERLAGET PLADEEPITEL MEDIALT FOR  
NORMALT TROMMEHINDE-NIVEAU"

SYMPTOMER:    INTERMITTERENDE FLÅD  
                      EVT. SMERTER  
                      HØRENEDSÆTTELSE  
                      EVT. KOMPLIKATIONER

---

---

---

---

---

---

---

---

## KRONISK OTITIS MEDIA

### ● CHOLESTEATOM:

DIAGNOSTIK:    OTOMIKROSKOPI  
                      AUDIOMETRI  
                      EVT. CT

(OFTE RANDSTILLET PERFORATION /  
RETRAKTION SV.T. ATTICUS ELLER  
SINUS ELLER TENSA CHOLESTEATOM)  
KNOGLEDESTRUKTION  
EPITELMEMBRANER/SÆK MED KERATIN

BEHANDLING:    SKAL OPERERES !  
                      (EXPLORATIV TYMPANOTOMI,  
                      MASTOIDEKTOMI, TYPE I,II,III  
                      EVT. RADIKAL KAVITET)

---

---

---

---

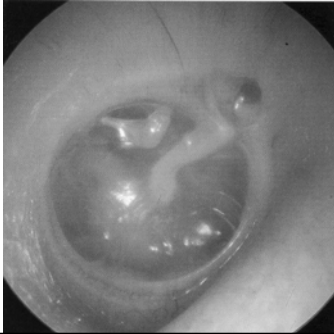---

---

---

---

RETRAKTION/ATROFI/AELEKTASE



---

---

---

---

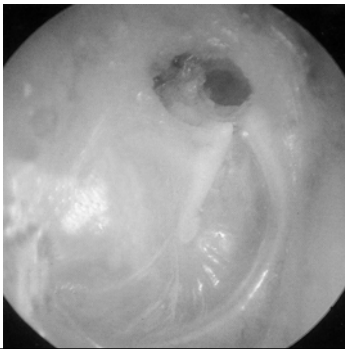
---

---

---

---

CHOLESTEATOM I FLACCIDA



---

---

---

---

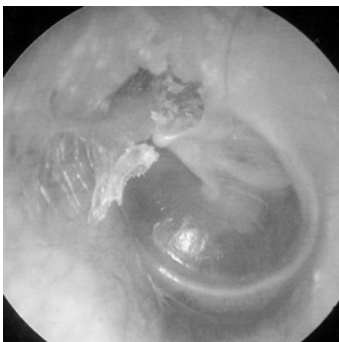
---

---

---

---

CHOLESTEATOM I FLACCIDA



---

---

---

---

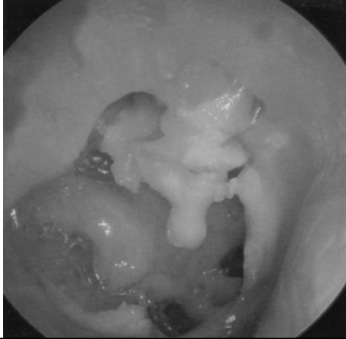---

---

---

---

## CHOLESTEATOM I MELLEMMØRET



---

---

---

---

---

---

---

---

## KRONISK OTITIS MEDIA

### ● SPECIFIKKE INFLAMMATIONER:

➢ TB-OTIT: SJÆLDEN, + LUNGE-TB

TYK, GUL TROMMEHINDE  
FLERE PERFORATIONER  
TYNDT SEKRET  
RELATIVT STORT HØRETAB  
OSTIT MED SEQUESTER

HISTOLOGI

MEDICINSK BEHANDLING

---

---

---

---

---

---

---

---

## KRONISK OTITIS MEDIA

### ● SPECIFIKKE INFLAMMATIONER:

➢ EOSINOFILT GRANULOM:

LED I LANGERHANS-CELLE HISTIOCYTOSE  
UNIFOKAL – MULTIFOKAL - FULMINANT  
OSTEOLYTISK PROCES  
ØREFLÅD  
PRURIGO-BESNIER LIGN. UDSLÆT

EVT. KIRURGI (MASTOIDEKTOMI)

RADIOTERAPI

CYTOSTATIKA, STEROID

---

---

---

---

---

---

---

---

## KRONISK OTITIS MEDIA

### ● KOMPLIKATIONER:

- MASTOIDITIS ACUTA
- PERIFER FACIALIS PARESE
- LABYRINTFISTEL – LABYRINTITIS
- MENINGITIS
- EPIDURAL ABSCES
- CEREBRAL ABSCES
- SINUS THROMBOPHLEBITIS

---

---

---

---

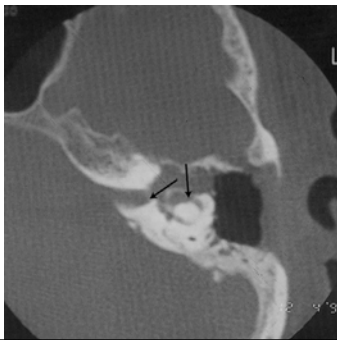
---

---

---

---

## CT: DESTRUKTION AF COCHLEA+ LATERALE BUEGANG



---

---

---

---

---

---

---

---

## KRONISK OTITIS MEDIA

### ● SEQUELAE OTITIDIS:

SES EFTER OPHELET SUPPURATIV OTIT  
DVS.

*INGEN INFLAMMATION  
INTET FLÅD*

- SYMPTOMER:      INGEN  
                                 HØRENEDSÆTTELSE

---

---

---

---

---

---

---

---

## KRONISK OTITIS MEDIA

### ● SEQUELAE OTITIDIS:

- DIAGNOSTIK: OTOMIKROSKOPI
  - ADHÆSIV OTIT
  - MYRINGOSCLEROSE
  - FIBROSE
  - RETRAKTION
  - PERFORATION
  - ATROFI
  - NORMAL
- AUDIOMETRI
  - OSSIKELKÆDEDEFEKT
  - NORMAL

---

---

---

---

---

---

---

---

## KRONISK OTITIS MEDIA

### ● SEQUELAE OTITIDIS:

- FORLØB: AKUT INFEKTION
- BEHANDLING: EXPLORATIV TYMPANOTOMI  
TYPE I,II,III
- DIFFERENTIAL-  
DIAGNOSE: OTOSCLEROSE

---

---

---

---

---

---

---

---

## OTOSCLEROSE

- EPIDEMIOLOGI: INCIDENS: 0.5 %  
KVINDER/MÆND: 2/1
- ÆTIOLOGI: ARV + ????
- PATOGENESE: FOKAL PATOLOGISK KNOGLEOMSÆTNING  
I LABYRINTEN SPEC. MED FIXATION AF  
STAPES-FODPLADEN
- SYMPTOMER: KONDUKTIVT HØRETAB  
EVT. PERCEPTIVT  
TINNITUS  
SVIMMELHED

---

---

---

---

---

---

---

---

## OTOSCLEROSE

➤ DIAGNOSE:  
NORMAL OTOMIKROSKOPI  
HØRETAB (BAS)  
MANGLENDE STAPEDIUS-  
REFLEX

➤ BEHANDLING:  
STAPEDOTOMI  
HØREAPPARAT

---

---

---

---

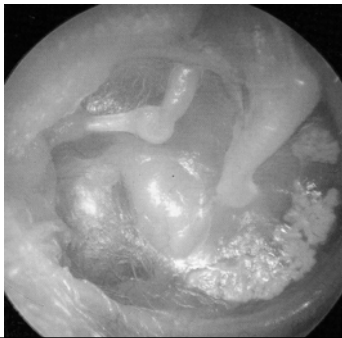
---

---

---

---

## ATELEKTASE/MYRINGOSCLEROSE



---

---

---

---

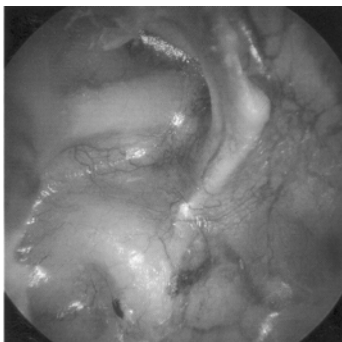---

---

---

---

## ATELEKTASE



---

---

---

---

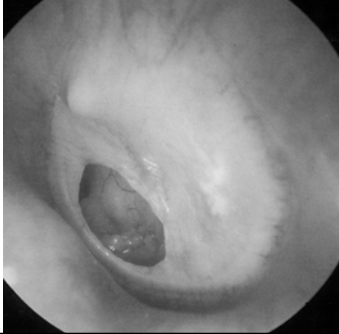---

---

---

---

PERFORATION/MYRINGOSCLEROSE



---

---

---

---

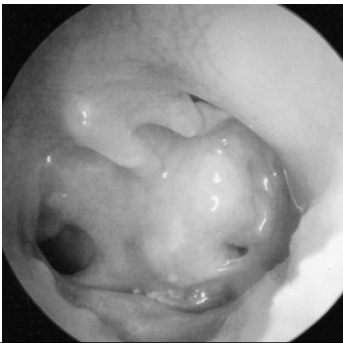
---

---

---

---

SUBTOTAL PERFORATION



---

---

---

---

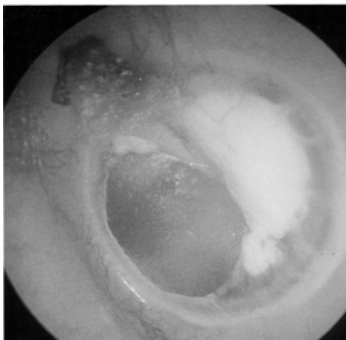---

---

---

---

ATROFI - MYRINGOSCLEROSE



---

---

---

---

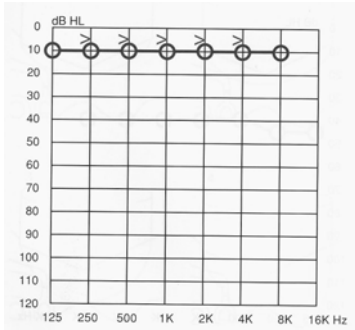
---

---

---

---

### HØRELSE: KRONISK OTIT



---

---

---

---

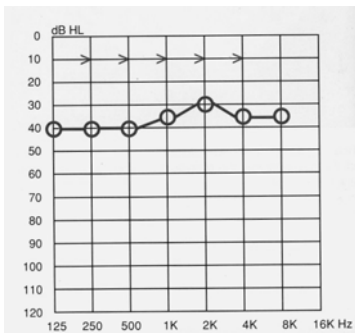
---

---

---

---

### HØRELSE: KRONISK OTIT



---

---

---

---

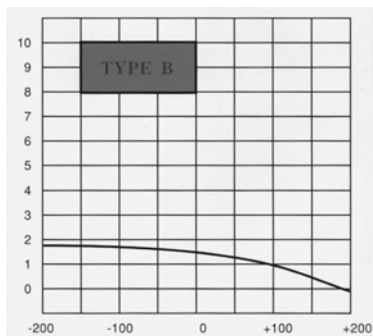
---

---

---

---

### TYMPANOMETRI: KRONISK OTIT



---

---

---

---

---

---

---

---