

## Oro- og rhinopharynx

Claus Gregers Petersen  
Overlæge, Øre-, næse- og halsafdeling H  
Speciale: næse og bihulekirurgi

---

---

---

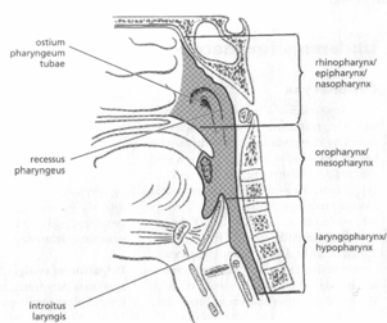
---

---

---

---

## Anatomi



---

---

---

---

---

---

---

## Vegetationes adenoides

### Definition:

Udtalt hyperplasi og/eller infektion af det lymfoide væv i tonsilla pharyngea i loftet og på bagvæggen af rhinopharynx.

---

---

---

---

---

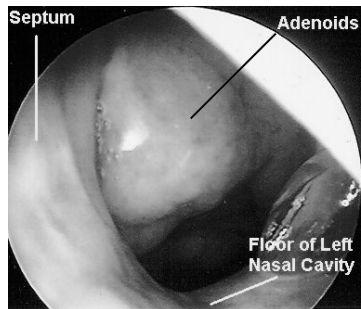
---

---

## Vegetationes adenoides

### Symptomer

- Nasalstenose
- Snorken
- OMS/OMA
- Forkølelse
- Natlig hoste



---

---

---

---

---

---

---

---

## Vegetationes adenoides

### Diagnose

- Adenoidt udseende
- Snøvlen
- Inspektion af oropharynx
- Posterior rhinoskopi
- Fiberskopi
- Digital eksploration
- Rtg. sideoptagelse

---

---

---

---

---

---

---

---

## Vegetationes adenoides

### Indikation for adenotomi

- Nasalstenose
- OMS

### Kontraindikationer

- Ganespalte
- Ganesejlsparsese

### Komplikationer

- Åbent snøvl

---

---

---

---

---

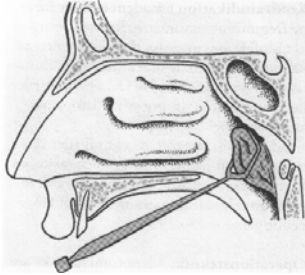
---

---

---

## Vegetationes adenoides

### Adenotomi



---

---

---

---

---

---

---

---

## Pharyngitis acuta

### Årsag

- Forkølelse
- Initieft ved influenza
- Streptokokker
- herpes

---

---

---

---

---

---

---

---

## Pharyngitis acuta

### Symptomer

- Tør kradsende fornemmelse i næsesvælget
- Synkesmerter (snyt/føde)
- Hoste
- Slim

---

---

---

---

---

---

---

---

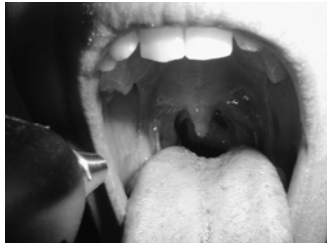## Pharyngitis acuta

### Objektivt

- Hyperæmi
- Glandel svulst

### Behandling

- Ingen
- Ingen tobak
- Symptom lindrende



---

---

---

---

---

---

---

---

## Pharyngitis chronica

### Årsager

- Recidiverende akutte pharyngitter
- Mundrespiration
- Allergi
- Tobak og alkohol
- Efter tonsillektomi
- Fonasteni (primær/sekundær)
- Maligne tumorer i luft og spiseveje
- Uræmi og diabetes

---

---

---

---

---

---

---

---

## Pharyngitis chronica

### Symptomer

- Som ved pharyngitis acuta, dog mildere

### Objektivt

- Hypertrofisk – røde lymfatiske ansamlinger i slimhinden og øget sekret
- Atrofisk – tør slimhinde, ferniseret, gulbrune skorper

---

---

---

---

---

---

---

---

## Pharyngitis chronica

### Behandling

- Afhængig af ætiologi
- Udelukke alvorlig sygdom
- Kraftig langvarig A-vitamin behandling
- Lapis pensling af hypertrofisk form

---

---

---

---

---

---

---

---

## Tonsillitis acuta

### Definition:

Akut inflammation af tonsillerne og deres omgivelser

---

---

---

---

---

---

---

---

## Tonsillitis acuta

### Årsager

- Virus
- Beta-hæmolytiske streptokokker gr. A
- Scarlatina
- Difteri
- Mononukleose
- Agranulocytose
- Influenza
- Morbilli

---

---

---

---

---

---

---

---

## Tonsillitis acuta

### Symptomer

- Synkesmerter
- Synkebesvær
- Otagi
- Feber
- Grødet tale

---

---

---

---

---

---

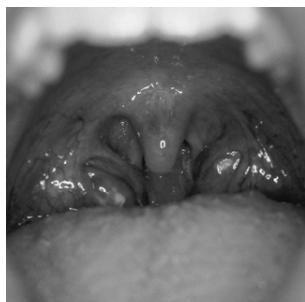---

---

## Tonsillitis acuta

### Objektivt

- Hyperæmi
- Hypertrofi
- Belægninger
- Foetor ex ore
- Glandel svulst



---

---

---

---

---

---

---

---

## Tonsillitis acuta

### Behandling

- Ingen
- Penicillin

### Symptomatisk

- Analgetika
- Blød/flydende kost

---

---

---

---

---

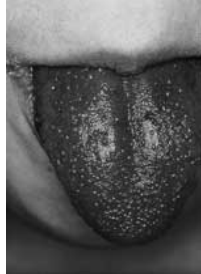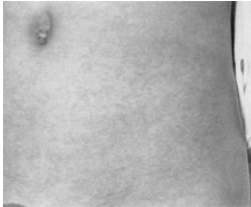---

---

---

## Scarlatina

- Tonsiller som ved Tonsillitis acuta
- Fintprykket follikulært eksanthem
- Hindbær tunge



---

---

---

---

---

---

---

---

## Mononucleosis Infectiosa

- Epstein Barr
- Halssymptomer sekundære (5-10 dage)
- Meget store og belagte tonsiller
- Generel glandel svulst
- Hepato-splenomegali
- Lymfocytose med atypiske lymfocytter
- Påvirket levertal
- Monospot
- Ampicillin giver eksanthem

---

---

---

---

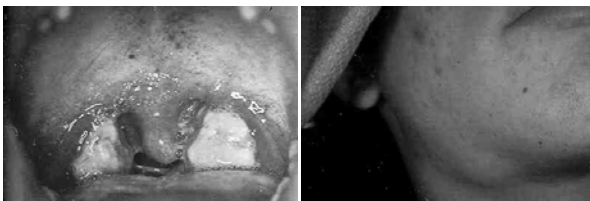
---

---

---

---

## Mononucleosis Infectiosa



---

---

---

---

---

---

---

---

### Tonsillitis ulcero-membranacea Vincent's angina

- Ensidig
- Ulcerøs
- Få almen symptomer
- Fusiforme bakterier og spirokæter
- Penicillin

---

---

---

---

---

---

---

---

### Agranulocytose og leukæmi

- Svær nekrotiserende ulcerøs tonsillitis

#### Difteri

- Hvidgule, flødeskindsagtige, tykke, fastsiddende belægnings
- Kan sprede sig uden for tonsillerne
- Moderat feber

---

---

---

---

---

---

---

---

### Komplikationer til tonsillitis

#### Immunologiske (beta-hæmolytiske streptokokker)

- Febris rheumatica
- Akut glomerulonephritis

#### De vigtige

- Abscessus peritonsillaris
- Abscessus parapharyngealis

---

---

---

---

---

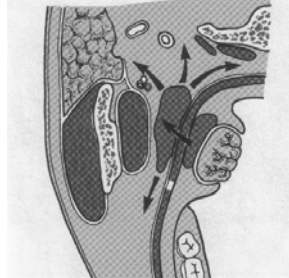
---

---

---

## Abscessus peritonsillaris

- Hyppig hos voksne
- Sjældent bilateral
- Normalt lokaliseret omkring øverste tonsilpol



---

---

---

---

---

---

---

---

## Abscessus peritonsillaris

### Symptomer

- Trismus
- Otalgji
- Ensidige synkesmerter
- Vedvarende feber
- Grødet tale
- Spytfloed
- Foetor ex ore

---

---

---

---

---

---

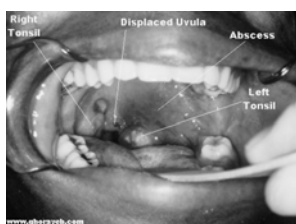
---

---

## Abscessus peritonsillaris

### Objektivt

- Trismus
- Asymmetrisk peritonsillær hævelse
- Forskydning af tonsil og uvula
- Adenit



---

---

---

---

---

---

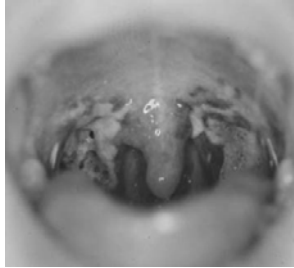
---

---

## Abscessus peritonsillaris

### Behandling

- Incision+ penicillin:
    - > 30 år
  - tonsillektomi á chaud:
    - < 30 år
- Tidligere recidiverende tonsillitis  
Tidligere absces



---

---

---

---

---

---

---

---

## Abscessus parapharyngealis

### Definition

- Absces lateralt for m. constrictor pharyngis

### Årsag

- Spredning fra tonsil, visdomstand, suppurerende lymfeknude

### Objektivt

- Medial forskydning af svælgvæggen

---

---

---

---

---

---

---

---

## Abscessus parapharyngealis

### Behandling

- Penicillin
- Tonsillectomia á chaud og spaltning af pharynxvæggen

### Komplikationer

- Sænkingsabsces langs karskeden til mediastinum
- Thrombophlebitis i vena jugularis interna

---

---

---

---

---

---

---

---

## Tonsillektomi

### Indikation

- Recidiverende akut tonsillitis, >2-3 tilfælde/år i 2 år
- Tonsillitis chronica hypertrophica (hypertrofia tonsillarum)
- Peritonsillær absces
- Mistanke om tonsil tumor
- "foetor ex ore"
- Tilbageholdende ved børn < 4 år

---

---

---

---

---

---

---

---

## Angiofibroma rhinopharyngis

- Benign, sjælden, drenge 10-20 års alderen

### Symptomer

- Nasalstenose
- Konduktivt høretab
- Epistaxis
- Indvækst i naboregioner

---

---

---

---

---

---

---

---

## Angiofibroma rhinopharyngis

### Objektivt

- Nasal endoskopi (puklet, grårød tumor)
- Cave biopsi

### Undersøgelser

- Carotisangiografi

### Behandling

- kirurgi

---

---

---

---

---

---

---

---

## Cancer rhinopharyngis

- Overvejende lavt diff. planocellulære karcinomer
- Sjælden (Grønland og Hong Kong x 25)
- Epstein Barr virus

---

---

---

---

---

---

---

---

## Cancer rhinopharyngis

### Symptomer

- Knude på halsen
- Konduktivt høretab, tinnitus
- Nasalstenose

### Behandling

- Strålebehandling
- Evt kemoterapi
- Radikal halsglandel dissektion

Fem års overlevelse for karcinomer er 25%

---

---

---

---

---

---

---

---

## Cancer oropharyngis

- 2/3 planocellulære karcinomer
- Non-Hodgkin lymfom
- Især ældre mænd
- Alkohol
- 50% i tonsiller, 25% i tungebasis og 25% i bløde gane
- Vokser infiltrativt ulcerende
- Metastaserer til specielt angulære glandler

---

---

---

---

---

---

---

---

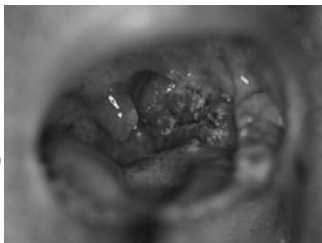
## Cancer oropharyngis

### Symptomer

- Hals glandel
- Smerter
- Synkebesvær

### Diagnose

- Inspektion (spejl, fiber, endoskopi i GA)
- Palpation
- biopsi



---

---

---

---

---

---

---

---

## Cancer oropharyngis

### Behandling

- Stråleterapi
- Ved resttumor eller recidiv evt kirurgi
- Kemoterapi ved lymfom

### 5 års overlevelse

- Tonsil 30%
- Tungebasis 25%

---

---

---

---

---

---

---

---

## Snorken

- Ca. 50% snorker, mænd tiltagende med alderen

### Årsag

- Muskelafslapning, tunge, gane og uvula

### Diagnose

- Søvnregistrering

### Behandling

- Vægt reduktion
- Lejring
- Undgå alkohol og relaxerende medikamina
- Septumoperation, UPPP

---

---

---

---

---

---

---

---

## Obstruktiv søvnapnø

### Definition

- Ophør af luftflow men fortsat thoraxbevægelser

### Prævalens

- 4% af mænd og 2% af kvinder, stigende med alderen

---

---

---

---

---

---

---

---

## Obstruktiv søvnapnøsyndrom

### Symptomer

- Dag træthed
- Hovedpine
- Hukommelse og koncentrationsevne
- Potens
- BT og kardiale lidelser

---

---

---

---

---

---

---

---

## Obstruktiv søvnapnøsyndrom

### Undersøgelser

- Søvnmonitorering
- TSH (myksødem)
- EKG

### Behandling

- CPAP
- Tracheotomi, yderst sjældent

---

---

---

---

---

---

---

---